

## PennHIP Report

Referring Veterinarian: Dr Amy Nicewonger Email: avslc2014@gmail.com	Clinic Name: Alpha Veterinary Services LLC Clinic Address: 150 Pittsburgh St. Uniontown, PA 15401 Phone: (724) 550-4005 Fax: (724) 550-4046
---	---

## Patient Information

Client: Hinterer, Melissa Patient Name: Daisy Reg. Name: Hinterer's She Loves Me Daisy PennHIP Num: 133047 Species: Canine Date of Birth: 06 Aug 2018 Sex: Female Date of Study: 18 Jul 2019 Date of Report: 18 Jul 2019	Tattoo Num: Patient ID: 11869 Registration Num: SS07137107 Microchip Num: 985112011507926 Breed: GOLDEN RETRIEVER Age: 11 months Weight: 57 lbs/25.9 kgs Date Submitted: 18 Jul 2019
--	---

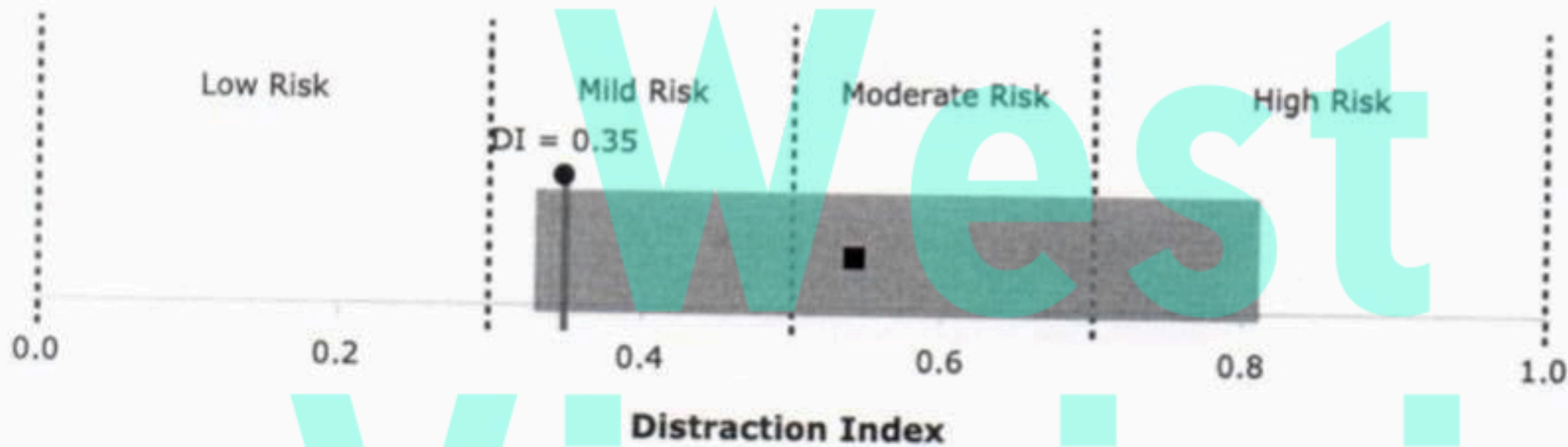
## Findings

Distraction Index (DI): Right DI = 0.35, Left DI = 0.32.  
 Osteoarthritis (OA): No radiographic evidence of OA for either hip.  
 Cavitation/Other Findings: No cavitation present.

## Interpretation

Distraction Index (DI): The laxity ranking is based on the hip with the greater laxity (larger DI). In this case the DI used is 0.35.  
 OA Risk Category: The DI is between 0.31 and 0.49. This patient is at mild risk for hip OA.  
 Distraction Index Chart:

### GOLDEN RETRIEVER



**BREED STATISTICS:** This interpretation is based on a cross-section of 20243 canine patients of the GOLDEN RETRIEVER breed in the AIS PennHIP database. The gray strip represents the central 90% range of DIs (0.33 - 0.81) for the breed. The breed average DI is 0.54 (solid square). The patient DI is the solid circle (0.35).

**SUMMARY:** The degree of laxity (DI = 0.35) falls within the central 90% range of DIs for the breed. This amount of hip laxity places the hip at a mild risk to develop hip OA. No radiographic evidence of OA for either hip.